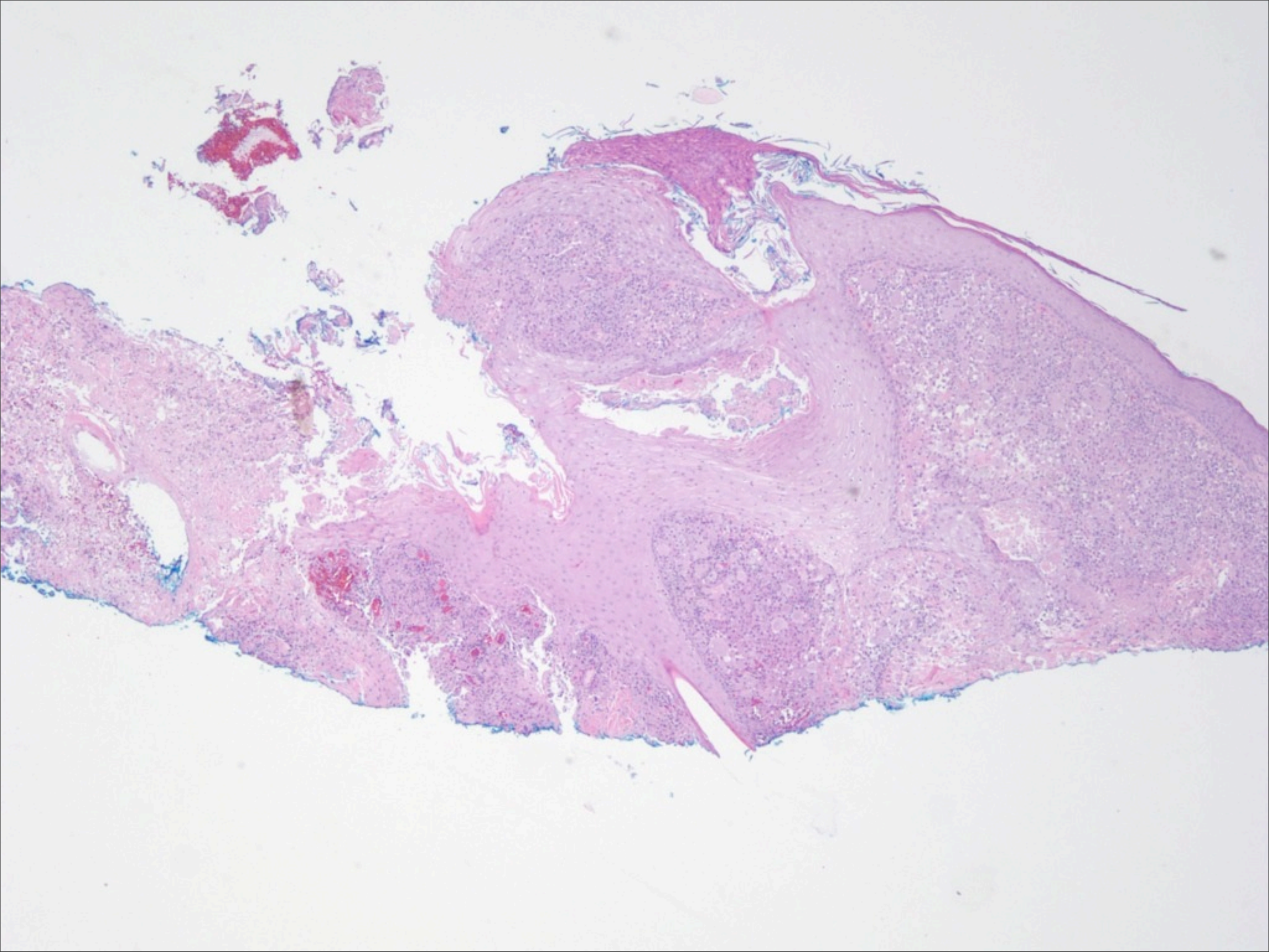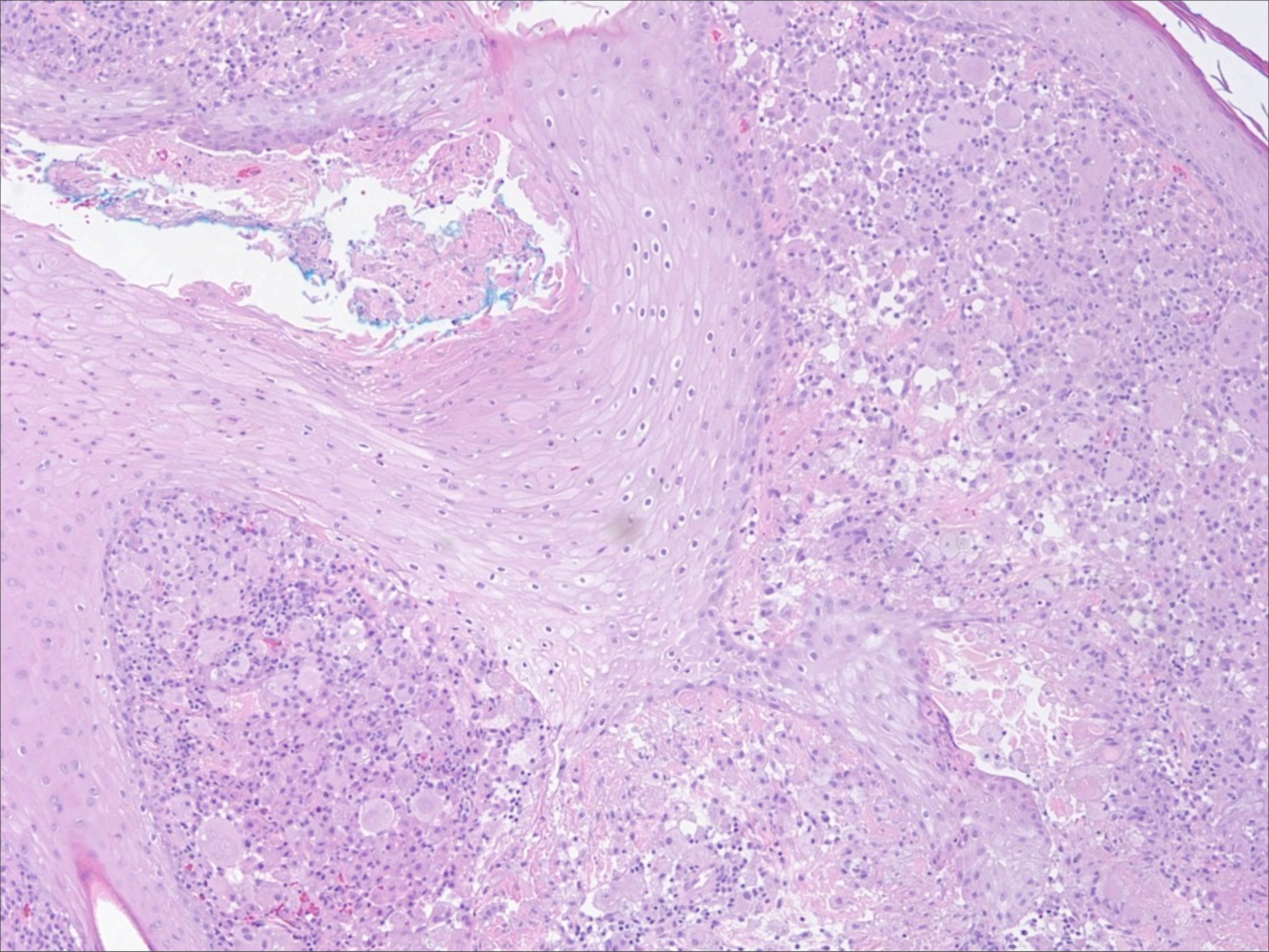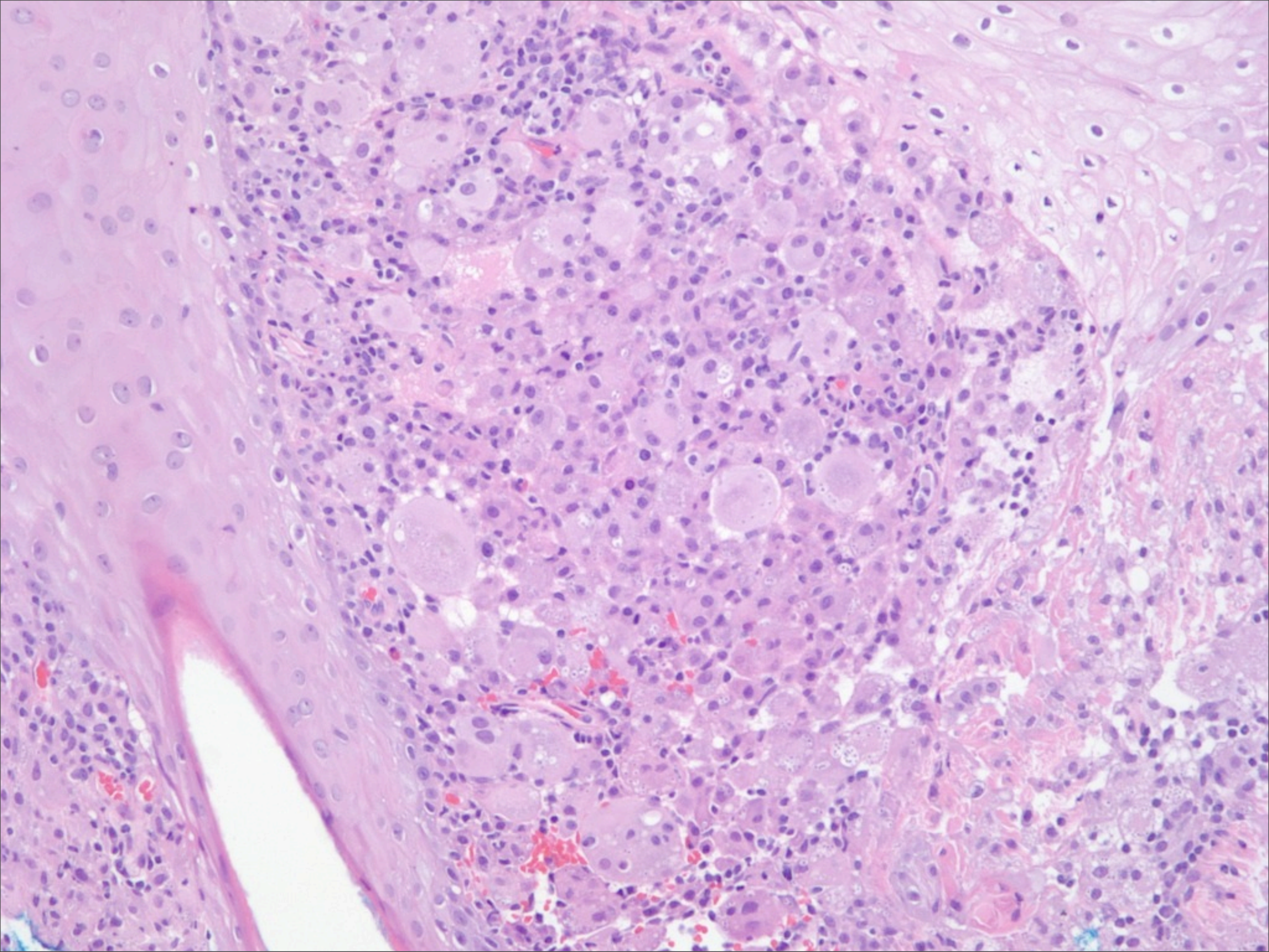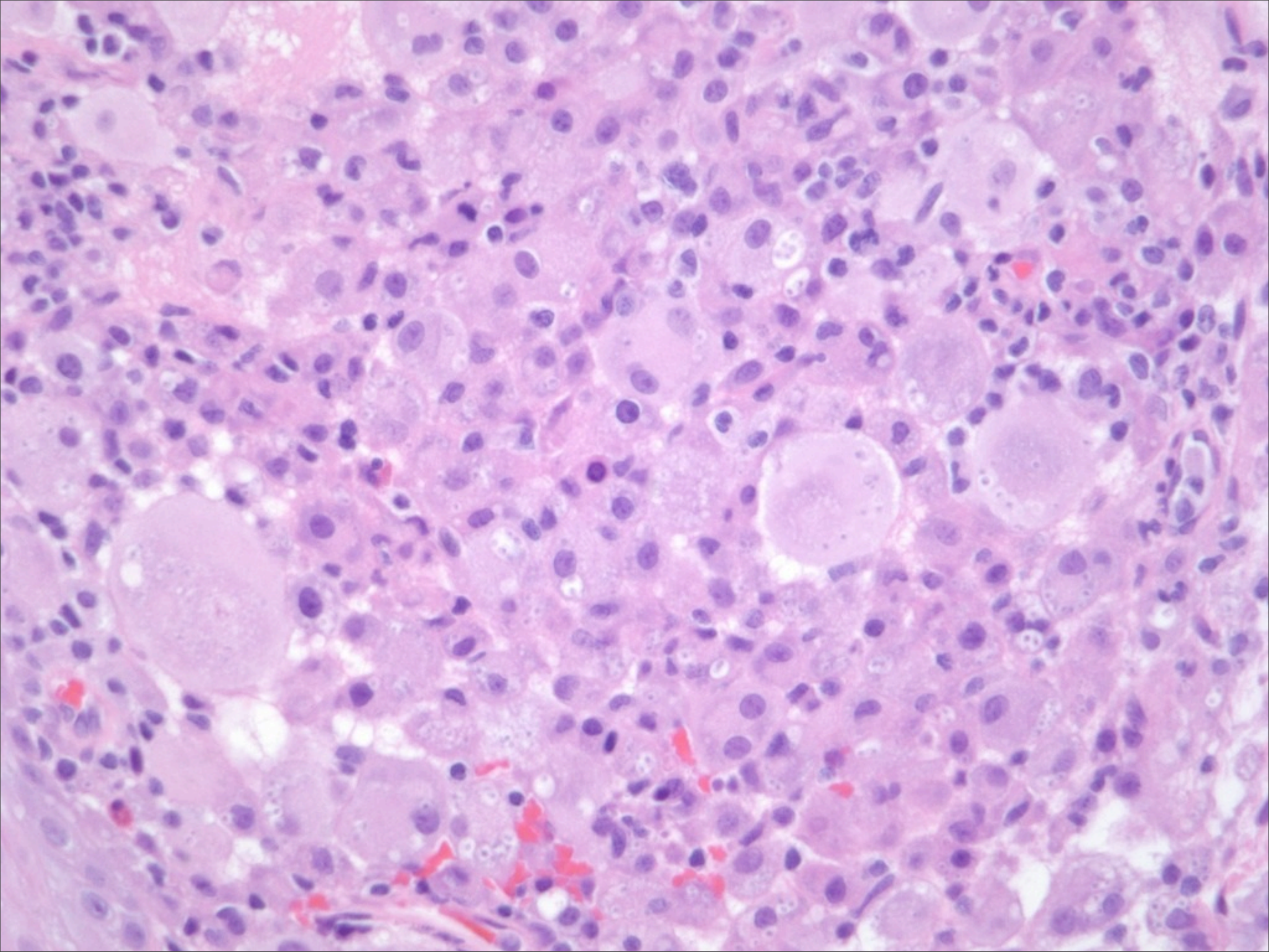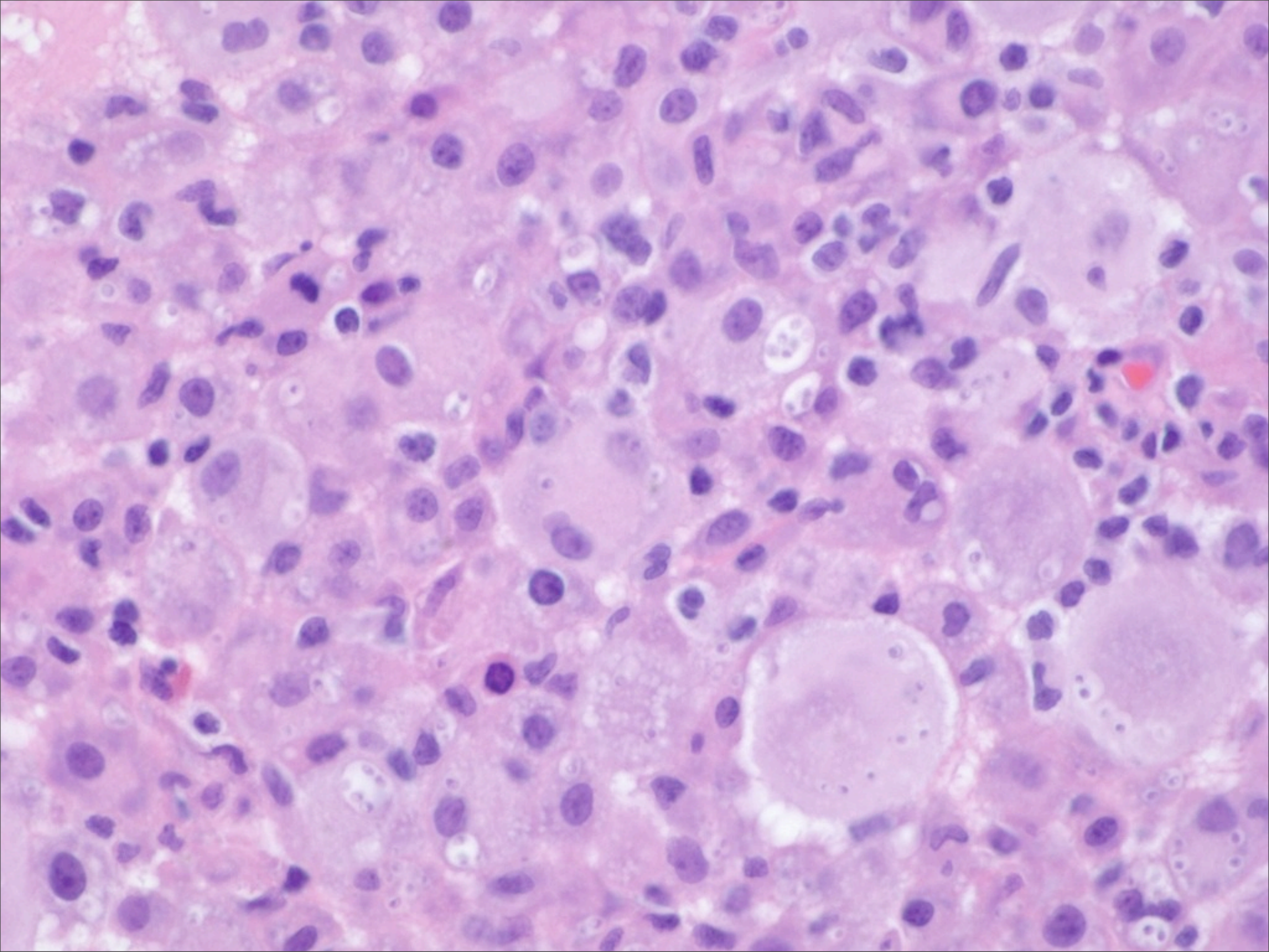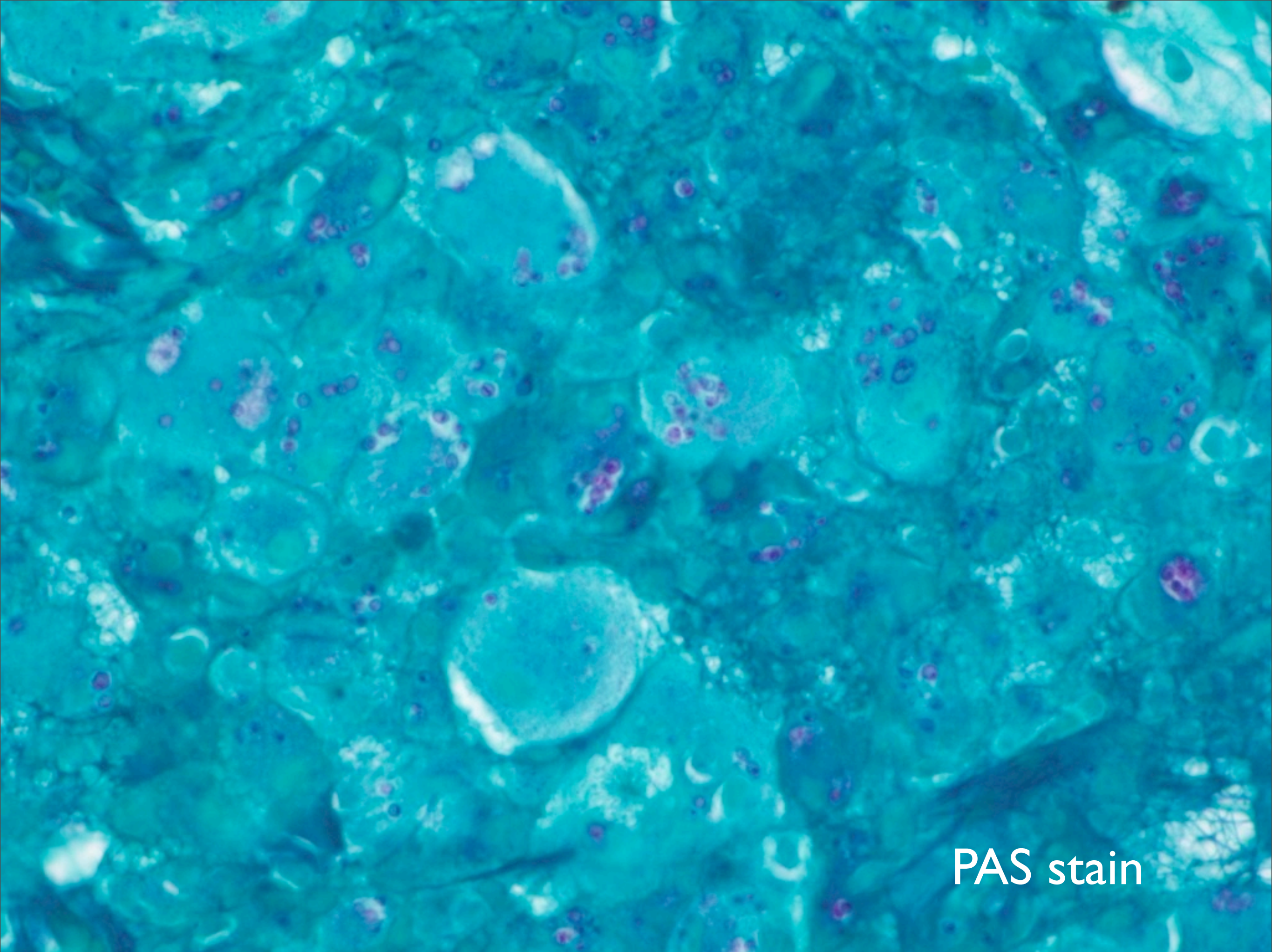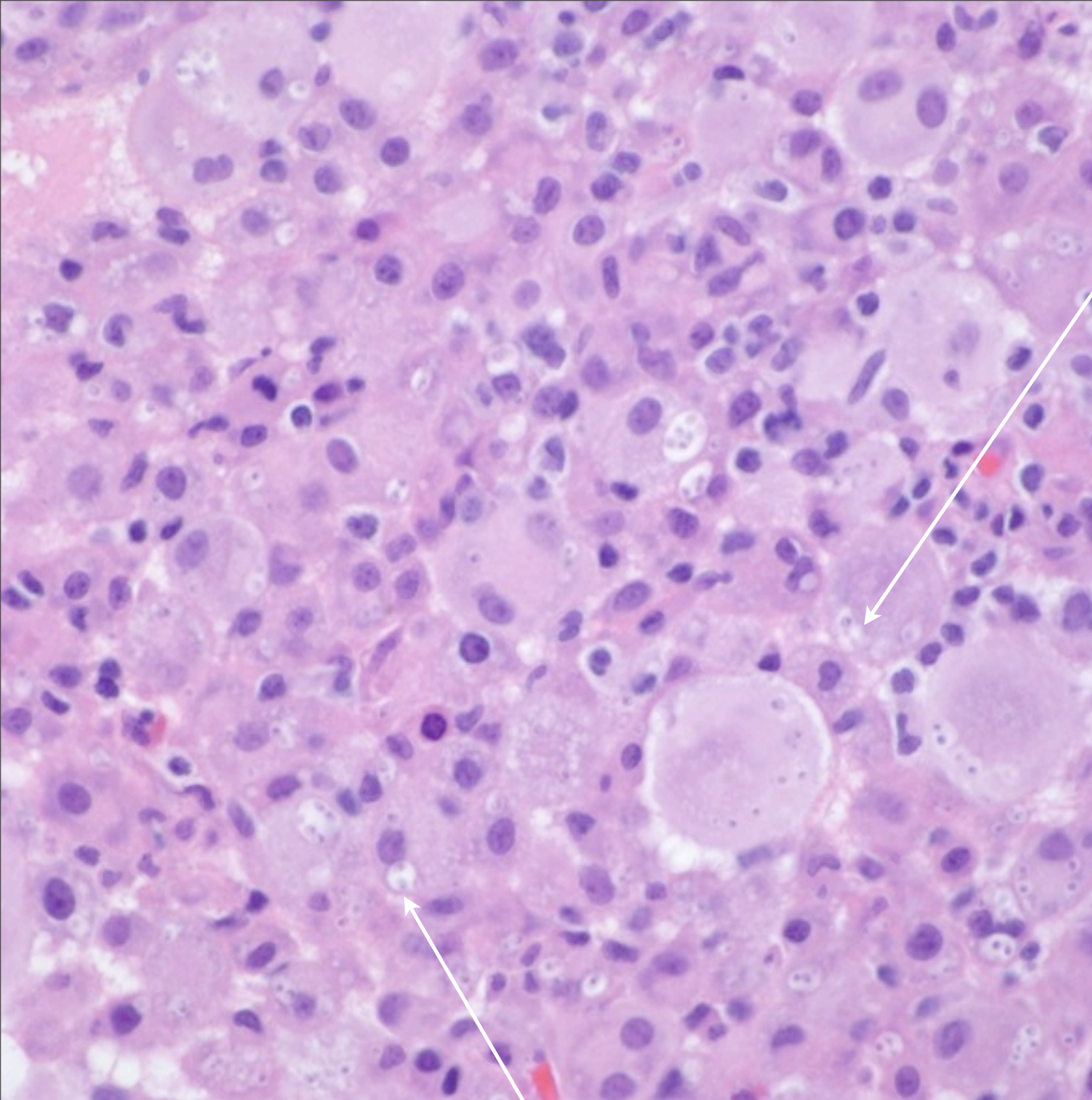


PAS stain

Histoplasmosis



Small organisms with clearing

Numerous histiocytes with organisms

Confirm with PAS or GMS stains